



Contents lists available at ScienceDirect

Journal of Hand Surgery Global Online

journal homepage: [www.JHSGO.org](http://www.JHSGO.org)

## Original Research

## Suture Button Suspensionplasty in the Treatment of Carpometacarpal Arthritis: A Retrospective Analysis of One Surgeon's Experience Over 9 Years

Nathan Walter, BS,<sup>\*</sup> Emily Duncan, BS,<sup>\*</sup> Mellisa Roskosky, PhD,<sup>†</sup> Tyler B. Smith, MPH, MSW,<sup>‡</sup> Michael S. Shuler, MD<sup>‡</sup><sup>\*</sup> Augusta University/Medical College of Georgia Partnership, Athens, GA<sup>†</sup> Bloomberg School of Public Health, Johns Hopkins University, Baltimore, MD<sup>‡</sup> Athens Orthopedic Clinic, Athens, GA

## ARTICLE INFO

## Article history:

Received for publication August 19, 2019

Accepted in revised form November 13, 2019

Available online January 8, 2020

## Key words:

Basilar thumb arthritis  
Carpometacarpal arthritis  
Carpometacarpal arthroplasty  
Suture button suspensionplasty  
Trapeziectomy**Purpose:** Trapeziectomy with suture button suspensionplasty (SBS) to treat thumb carpometacarpal (CMC) arthritis has been proposed as an alternative to ligament reconstruction tendon interposition. There have been limited large-scale or long-term reports regarding SBS outcomes. Single-surgeon intermediate follow-up is reported.**Methods:** We conducted a retrospective review of patients undergoing SBS procedures by a single surgeon. Implant manufacturer and postoperative immobilization protocol were recorded. Surgical outcomes, complications, and revision procedures were identified. Postoperative Disabilities of the Arm, Shoulder, and Hand scores were collected.**Results:** A total of 242 SBS surgeries were included, involving 215 patients, average age 64.82 years (range, 42–86 years). Average follow-up was 35 ± 25 months. In all, 183 Arthrex and 59 Stryker systems were used, 42 of which were immobilized for 6 weeks after surgery and 200 of which were mobilized at 2 weeks afterward. Postoperative Disabilities of the Arm, Shoulder, and Hand surveys were completed by 122 patients (57%), with an average score of 12. No scaphometacarpal abutment was reported. Thirteen complications were reported (5%), 7 of which were implant-associated (3%) and 6 of which were not (2%). Implant-associated complications consisted of 3 suture button pull-outs, 2 thumb–index metacarpal abutments, one suture tail irritation, and one index metacarpal fracture. Operative revision was required in 4 of 7 implant-associated cases and 5 of 6 non–implant associated cases. No suture button pull-outs required revision surgery.**Conclusions:** Results for a large series of SBS for CMC arthroplasty with intermediate follow-up revealed excellent clinical outcomes and low complication rates.**Clinical relevance:** Suture button suspensionplasty as an alternative to ligament reconstruction tendon interposition may be a viable option for treating thumb CMC arthritis. In addition, a technique to manage thumb–index metacarpal abutment is described.Copyright © 2019, THE AUTHORS. Published by Elsevier Inc. on behalf of The American Society for Surgery of the Hand.  
This is an open access article under the CC BY-NC-ND license (<http://creativecommons.org/licenses/by-nc-nd/4.0/>).

Thumb carpometacarpal (CMC) arthritis is the second most common arthritis of the hand, affecting 1 in 4 women and 1 in 12 men.<sup>1</sup> Because of its inherent mobility and associated load bearing

in pinch, the thumb CMC joint is particularly vulnerable to arthritic changes. Several ligaments establish trapeziometacarpal joint stability, the most important of which is the volarly located anterior oblique ligament. Laxity of this ligament has been shown to correlate with the development of CMC arthritis.<sup>2,3</sup>

There are several treatment options for CMC arthritis. Conservative measures include activity modification, placement of an orthosis, nonsteroidal anti-inflammatory drugs, and steroid injection. Many surgical interventions exist, but the reference standard is considered to be trapeziectomy with ligament reconstruction

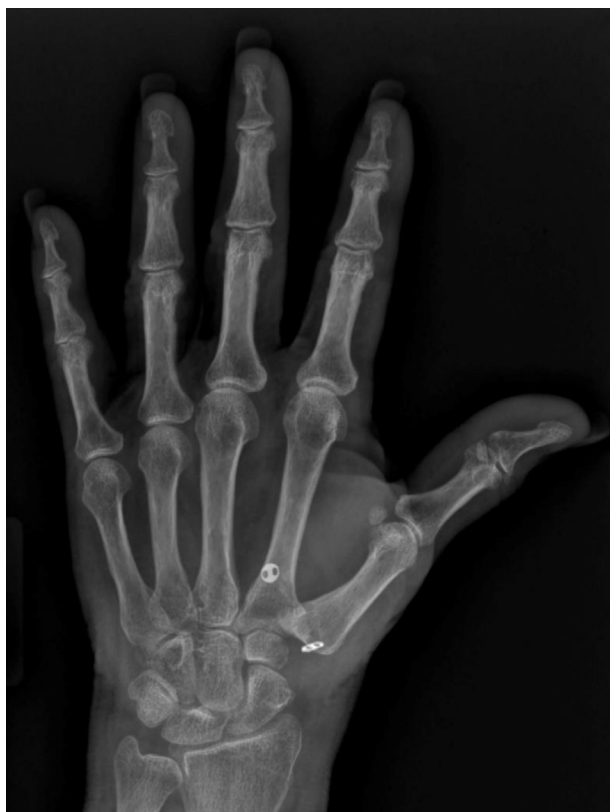**Declaration of interests:** No benefits in any form have been received or will be received by the authors related directly or indirectly to the subject of this article.

**Corresponding author:** Michael S. Shuler, MD, Athens Orthopedic Clinic, 1765 Old West Broad Street, Building 2, Suite 200, Athens, GA 30606.

E-mail address: [msimmss@hotmail.com](mailto:msimmss@hotmail.com) (M.S. Shuler).

<https://doi.org/10.1016/j.jhsg.2019.11.002>

2589–5141/Copyright © 2019, THE AUTHORS. Published by Elsevier Inc. on behalf of The American Society for Surgery of the Hand. This is an open access article under the CC BY-NC-ND license (<http://creativecommons.org/licenses/by-nc-nd/4.0/>).



**Figure 1.** Placement of suture button suspension at the time of thumb CMC arthroplasty. Posteroanterior view of the thumb after SBS for CMC arthroplasty, showing a well-placed suture button at the corner of the thumb metacarpal and flare of the index metacarpal base. The scaphometacarpal space is well-preserved.

and tendon interposition (LRTI) using the flexor carpi radialis tendon.<sup>1,3</sup> In addition, other techniques have been developed using other donor sites, such as the abductor pollicis longus or only half of the flexor carpi radialis.<sup>4,5</sup> A promising alternative to LRTI is trapeziectomy with suture button suspensionplasty (SBS). As with LRTI, excising the trapezium removes half of the arthritic joint, which alleviates arthritis-related pain.<sup>1</sup> Passing a suture bridge through the base of the thumb and index metacarpals suspends the thumb metacarpal, preventing proximal migration and abutment against the scaphoid without the need to procure a donor tendon for suspension and the morbidity associated with it (Fig. 1).

Studies supporting the efficacy of trapeziectomy with SBS are limited. Cadaveric studies showed that SBS provides equal, if not greater, maintenance of trapezial space height after trapeziectomy compared with LRTI.<sup>6–8</sup> In a study comparing trapeziectomy and flexor carpi radialis with abductor pollicis longus side-to-side tendon transfer with or without SBS, DeGeorge et al<sup>9</sup> found that the 2 procedures resulted in similar outcomes for pain, grip strength, and functionality, but that using SBS better preserved trapezial space height. Other *in vivo* studies also purported superior postoperative trapezial space height as an advantage to SBS, in addition to well-preserved range of motion and earlier mobility of the operative digit.<sup>10–12</sup> Reported complication rates for trapeziectomy with SBS range from roughly 2% to 11%.<sup>9,13,14</sup>

This study presents a retrospective analysis of one surgeon's experience over 9 years performing trapeziectomy with SBS to treat CMC arthritis and offers insight into intermediate-range outcomes for a large number of procedures. It also describes the learning curve for modifications and adaptations to the surgical procedure

**Table 1**  
Participant Characteristics

Variable	Count
Gender	
Male	65
Female	150
Eaton stage	
II	38
III	113
IV	91
Race	
White	200
Black	3
Asian	0
Declined/no answer	12
Ethnicity	
Hispanic/Latino	0
Non-Hispanic/Latino	179
Declined/no answer	36
Concurrent procedures	
Carpal tunnel release	79
MCP volar plate repair	41
de Quervain release	36
Interphalangeal arthrodesis	14
Trigger thumb release	7

and postoperative therapy protocol. Complication rates and a novel procedure to address a unique complication associated with the SBS, thumb–index metacarpal abutment, are also described.

## Materials and Methods

We obtained institutional review board approval. Inclusion criteria included all patients who received trapeziectomy and SBS from a single surgeon using Current Procedural Terminology code 25447. All patients were Eaton stage 2 or greater (Table 1) and had previously failed conservative management with a combination of nonsteroidal anti-inflammatory drugs, placement of an orthosis, and/or corticosteroid injection. Exclusion criteria included preexisting regional trauma or injury, additional reconstructive surgical treatment of non-CMC arthritis, and major unrelated comorbidity. Records meeting inclusion criteria were reviewed for the presence of continued pain or dysfunction, subsequent operative procedures, and radiographic abnormalities such as device failure or scapho-trapezial abutment. Complications were categorized as implant associated or non–implant associated according to their etiology. Complications resulting from implant performance or placement (including button pull-through or pull-out, thumb–index metacarpal abutment, suture irritation, and index metacarpal fracture through the tunnel) were labeled as implant associated, whereas those resulting from inherent operative risk (including thumb radial sensory nerve neuritis or dorsal thumb metacarpal spur pain) were labeled as non–implant associated.

Disabilities of the Arm, Shoulder, and Hand (DASH) questionnaire scores were on file for patients ( $n = 98$ ) who participated in postoperative hand therapy at the treating surgeon's practice. We attempted to collect DASH scores from participants without one on file; 24 additional DASH scores were collected through phone administration. After an initial trial period, the treating physician (M.S.S.) has converted to using only the SBS based on perceived improved stability and patient satisfaction, as well as reduced operative time and complications.

## Surgical technique

A curvilinear incision was made along the glabrous skin edge at the base of the thumb. The thenar musculature was sharply peeled off the capsule of the CMC joint. A longitudinal capsulotomy was

performed, followed by the trapeziectomy. The guidewire was driven from the radial proximal corner of the thumb metacarpal (MC) through the thumb metacarpal and then through the index MC and out the dorsum of the hand between the index and middle finger MCs. When placing the guidewire, the thumb MC is maximally adducted to allow proper placement on the index MC. A small skin incision is placed at the exit of the guidewire. The guidewire is overdrilled and then pulled out through the end of the drill bit, with the drill bit left in place to allow passage of the suture bridge without losing alignment of the 2 MCs.

The suture bridge was passed, tensioned, and secured. Approximately 10 to 12 half-hitches were used to secure the SBS. More half-hitches were used to allow for a longer knot stack, which facilitated burying the stack within the soft tissue. After tensioning and placement of the first half-hitch, a fluoroscopic image was obtained to ensure that 2 to 3 mm of space was present between the thumb and index MC to prevent overtightening. The knot stack was buried and 2-0 absorbable, synthetic, braided suture was used to close the CMC capsule and the fascia between the index and middle finger MC if the knot was placed between the 2 MCs. The skin was closed using 4-0 nylon simple sutures, which were removed after 2 weeks.

During surgery, the stability of the SBS was verified through manual attempts to cause thumb metacarpal–scaphoid abutment by axial loading using both direct visualization and fluoroscopic imaging. Based on improved stability compared with LRTI, a reduction in postoperative use of an orthosis or casting was initiated during the study period. For the first 4 years, a postoperative plaster orthosis for 2 weeks followed by casting for an additional 4 weeks was used, similar to a standard LRTI postoperative protocol.<sup>15,16</sup> After 6 weeks, certified hand therapy was initiated, and an orthosis was used for comfort for approximately 4 to 8 weeks after cast removal. As the surgeon became more comfortable with the technique and confident with the stability obtained during surgery, the postoperative immobilization period was reduced. For the last 5.5 years, postoperative use of a plaster splint was limited to only 2 weeks. Certified hand therapy, including a removable orthosis, was initiated after 2 weeks. The patient was weaned from the orthosis according to comfort at 4 to 6 weeks after surgery.<sup>15,16</sup> Follow-up visits consisted of a radiographic examination of button placement and thumb metacarpal–scaphoid space maintenance, as well as pain and functional evaluations.

Additional comorbidities such as de Quervain tenosynovitis, carpal tunnel syndrome, and metacarpophalangeal (MCP) hyperextension were addressed at the initial surgical procedure (Table 1). De Quervain tenosynovitis release was performed using a separate incision over the first dorsal compartment. Carpal tunnel release was typically performed using the MicroAire endoscopic system (MicroAire, Charlottesville, VA). Metacarpophalangeal hyperextension was addressed through a Brunner incision over the volar flexion crease. The A1 pulley was released and a bone anchor was used at the MC neck to repair the lax volar plate. The guidewire included in the SBS kit was used to maintain approximately 30° of flexion at the MCP joint for 4 weeks after surgery. If preexisting painful arthritis was present at a lax MCP, arthrodesis was performed using a headless compression screw. Currently, despite arthrodesis or pinning, patients are still transitioned into an orthosis at 2 weeks after surgery.

In cases of postoperative thumb–index finger metacarpal abutment, a previously unreported technique was used to alleviate painful symptoms associated with thumb–index metacarpal abutment. After osteophyte excision, a palmaris longus graft was used as an interpositional graft between the metacarpals around the intact suture bridge. A dorsal incision was made over the site of abutment between the thumb and index metacarpal bases; blunt

dissection was performed down to the thumb and index dorsal cortex. Any prominent osteophytes were resected (Fig. 2A). The palmaris longus autograft was harvested through 2 transverse incisions at the palmar wrist crease and the junction of the mid and distal third of the forearm. Approximately 10 cm of palmaris graft were harvested. A medium ConMed rotator cuff repair suture retriever (Utica, NY) was used to pass the graft around the suture bridge 3 times (Fig. 2B). The graft was then passed through itself in a Pulvertaft weave manner and sutured to itself (Fig. 2C). The excess arms were trimmed to approximately 1 cm on each side and passed volarly between the 2 metacarpals. The dorsal capsule was sutured back over the interposition using a 2-0 suture. The skin was closed using 4-0 nylon. Immobilization for 2 weeks was employed followed by a standard postoperative mobilization protocol as per primary CMC arthroplasty.

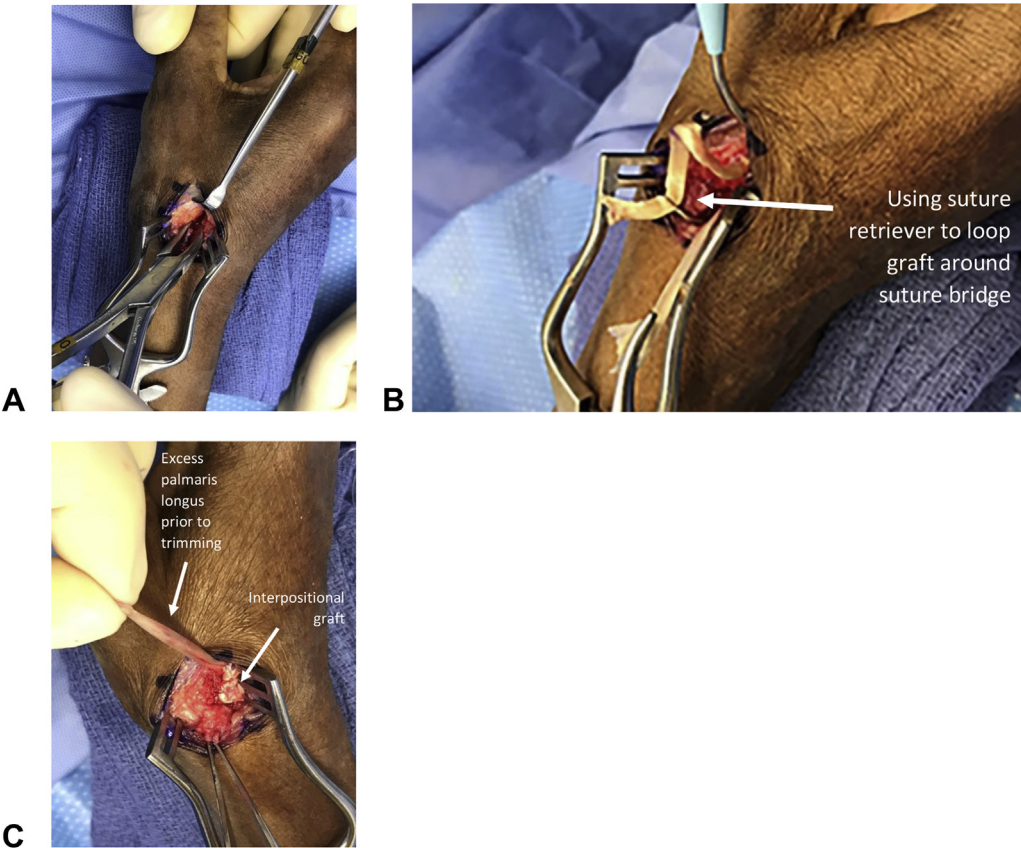
## Results

Of 261 total SBS procedures performed by the treating physician, 242 met the study's inclusion and exclusion criteria. These 242 surgeries involved 215 patients (150 women and 65 men), average age 65 years (range, 22–86 years) (Table 1). Two different suture button constructs were used: the first 183 patients were treated with a mini TightRope (Arthrex, Naples, FL), and an additional 59 were performed using the CMC CableFix Xpress (Stryker, Kalamazoo, MI). Average time from the date of surgery to the last follow-up visit was  $35 \pm 25$  months. The DASH scores were completed by 122 patients (57%), with an average score of  $12 \pm 15$  at an average of  $30 \pm 26$  months after surgery. All 242 procedures had postoperative radiographic follow-up at a median of 8 months (interquartile range, 3.5–18.5 months).

Of 242 total surgeries, 13 complications were identified and categorized (5%) (Table 2). No scaphometacarpal abutment was seen in any subjects in follow-up radiographs. Seven complications were associated with implants (3%) and 6 were not (2%). Implant-related complications included button pull-through or pull-out ( $n = 3$ ), thumb–index metacarpal abutment ( $n = 2$ ), suture irritation ( $n = 1$ ), and index metacarpal fracture through the tunnel ( $n = 1$ ). Non-implant related complications included thumb radial sensory nerve neuritis at the trapeziectomy site ( $n = 3$ ) and dorsal thumb metacarpal spur pain ( $n = 3$ ). Patients elected for operative revision in 4 of 7 implant-associated and 5 of 6 non-implant associated cases. Only one complication, caused by a non-implant associated bone spur, occurred in the 6-week immobilization group; all others occurred in the 2-week immobilization group. No complications were discovered through follow-up phone calls that were not already known and addressed through the course of standard postoperative care.

## Discussion

This study reports intermediate-term follow-up for a large series of SBS for CMC arthroplasty and contributes to the growing body of evidence in favor of SBS for the treatment of CMC arthritis.<sup>9,13,14,17</sup> It also provides a reference for a total complication rate of 5%, which coincides with complication rates for trapeziectomy with SBS reported by other studies (2% to 11%)<sup>9,13,14</sup> and appears to be favorable compared with published complication rates of LRTI (19% to 32%).<sup>18</sup> This was not a randomized comparative study, so superiority cannot be determined. This study also represents a single surgeon's experience and learning curve for this procedure. Based on intraoperative observations of SBS stability with axial loading, the need for extended (6-week) immobilization was considered unnecessary. A direct comparison of complications between the first 42 patients who were immobilized for 6 weeks



**Figure 2.** Addressing thumb–index metacarpal abutment using a palmaris longus autograft. **A** Initial steps require a dorsal incision over the site of abutment and the resection of any prominent osteophytes while protecting the suture bridge. **B** Passing the palmaris longus autograft around the suture bridge 3 times using a suture passer. **C** Passing the graft through itself in a Pulvertaft weave manner and suturing it to itself to create an interpositional graft between the bases of the 2 metacarpals.

**Table 2**  
Overview of Complications

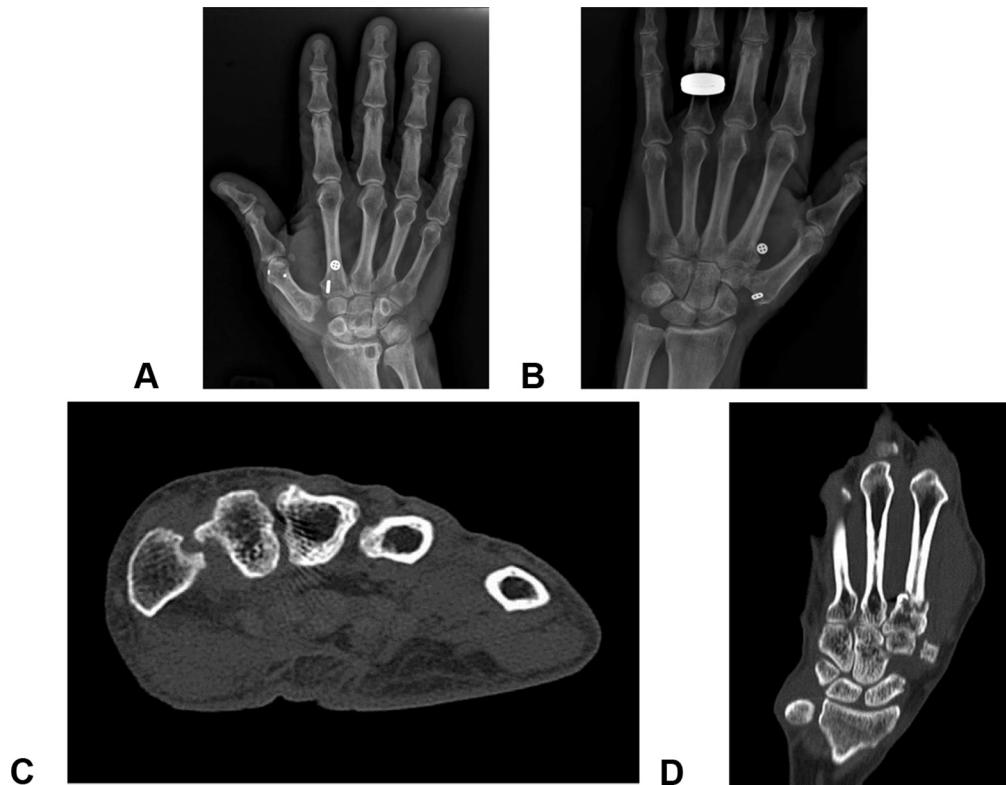
Category	Number (Rate)	Type	6-Week Immobilization		2-Week Immobilization	
			Number	Surgery Required	Number	Surgery Required
Implant associated	7 (3%)	Abutment	0	0	2	2
		Button pullout	0	0	3	0
		Suture irritation	0	0	1	1
		Index metacarpal fracture	0	0	1	1
Non-implant associated	6 (2%)	Neuritis	0	0	3	2
		Bone spur	1	1	2	2

and the following 200 who had 2 weeks of immobilization was not possible owing to the low complication rate and other potential confounding variables. In addition, an implant change was initiated because of the suture knot and tail location. The Mini TightRope requires knot placement between the index and middle finger metacarpals. Burying the suture below the interosseous fascia requires an extra step and results in one reoperation owing to irritation. The CMC CableFix knot is located at the thumb metacarpal base and is easily buried at the trapeziectomy site. In addition, throwing 10 to 12 half-hitches allows for a longer knot stack that is more capable of being tucked into the trapeziectomy space.

A review of implant-related complications in the current study showed that the most common complication was button pull-out ( $n = 3$ ). Two buttons pulled through the base of the thumb as a result of malrotation of the oval button, allowing it to pass back

through the bone tunnel (Fig. 3A). In addition, one pulled through the index metacarpal cortex as a result of poor tunnel placement and a thinned radial cortex on the index metacarpal (Fig. 3B). None of the 3 pull-outs required additional surgery, and all 3 patients were asymptomatic at final follow-up (average of 22 months). Pull-out occurred between the 2- and 6-week follow-up visits. It is possible that the temporary stabilization achieved by the SBS could mimic the Kirschner wire in a standard hematoma arthroplasty.

The second most common complication in the current study associated with SBS CMC arthroplasty was thumb–index metacarpal abutment ( $n = 2$ ). These complications were discovered based on continued postoperative pain at the 3-month follow-up appointment. Oblique radiographs centered at the interval between the thumb–index metacarpal, along with computed tomography, were used to confirm abutment (Fig. 3C). Abutment



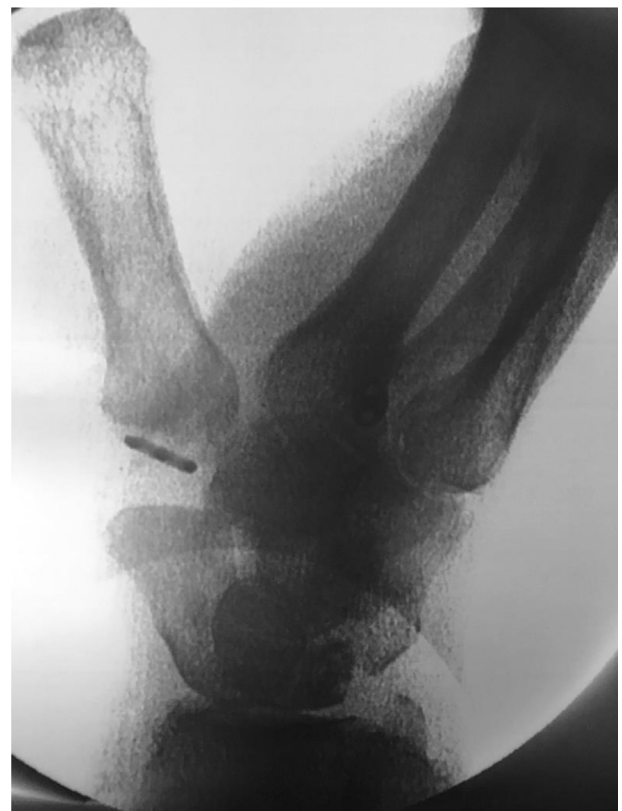**Figure 3.** Complications associated with SBS for CMC arthroplasty. Representative images demonstrating complications of SBS for CMC arthroplasty, including **A** SBS button pull-out through the thumb, **B** SBS button pull-out through the index metacarpal, **C** thumb index metacarpal abutment, and **D** index metacarpal fracture.

occurs as a result of overtightening suture tails when tightening the suture bridge. With excessive force, the thumb metacarpal base can be compressed against the index metacarpal, resulting in pain at the point of contact. Intraoperative fluoroscopy can be used to ensure 2 to 3 mm of space is present between the metacarpals before tying the knot in the SBS (Fig. 4). If abutment is seen on fluoroscopy, the tension should be relaxed before tying the knot. In all cases, unappreciated osteophytes on either the ulnar side of the thumb metacarpal or the radial side of the index metacarpal resulted in abutment (Fig. 3C).

In both abutment cases, a previously unreported technique was successfully employed to alleviate the painful symptoms associated with thumb–index metacarpal abutment. To ensure all osteophytes were removed and adequate separation was achieved, gentle traction was applied using a lamina spreader while taking care not to over-distract the intermetacarpal space. The suture button was visualized and protected during osteophyte resection. After osteophyte excision, a palmaris longus graft was used as an interpositional graft between the metacarpals around the intact suture bridge.

The single index metacarpal fracture case reported here was diagnosed on plain films at 10 weeks after surgery. The patient had increasing pain after assisting with a move to another residence. Computed tomography scan confirmed a transverse shaft fracture originating from the ulnar cortex of the index metacarpal (Fig. 3D). Revision surgery with open reduction internal fixation allowed for osseous union at 6 weeks. Other studies reported similar complications for SBS, including neuropathy, index metacarpal fracture, implant and suture irritation, and unappreciated osteophytes.<sup>9,13,14</sup>

Several limitations to our study are notable. Only 57% of patients completed postoperative DASH questionnaires, and because no baseline scores were collected or available, comparisons with more recent postoperative scores were impossible. Although all patients



**Figure 4.** Intraoperative fluoroscopy can be used to ensure that 2 to 3 mm of space is present between metacarpal before tying the knot in the SBS.

were explicitly instructed to contact the treating surgeon's office regarding concerns or unexpected changes in function or pain at treatment discharge, we cannot rule out additional undiscovered complications. Financial concerns or other factors may have prevented some patients from seeking follow-up care. Finally, without a control cohort, definitive comparisons with procedures such as LRTI cannot be made. Although a single surgeon limits variability in technique and follow-up methodology, the ability to extrapolate outcomes to all surgeons may require additional studies. Moreover, 2 unique implants with different characteristics were pooled in the current study. There was no comparison group for trapeziectomy alone; consequently, the necessity of the SBS cannot be established. Nevertheless, complications associated with the use of the implants were documented.

Despite these limitations, this longitudinal report of a single surgeon's experience from initial procedure completion to post-operative follow-up and therapy modifications offers strong support for the use of the technique. Clinically, neither implant offered benefits over the other except for knot placement at the trapeziectomy site with the Stryker implant. Because of low complication rates, learning curves, and differences in follow-up length between the implants used, direct comparisons were limited and not statistically different. This study offers intermediate to long-range feasibility data and evidence for this technique; however, more prospective, large-series data are needed to validate SBS definitively for the management of CMC arthritis.

## Acknowledgments

The authors would like to acknowledge the invaluable contribution of Wendy Wynne, LPN in assisting with surgical procedures and patient care.

## References

- Shuler MS, Luria S, Trumble TE. Basal joint arthritis of the thumb. *J Am Acad Orthop Surg.* 2008;16(7):418–423.
- Doerschuk SH, Hicks DG, Chinchilli VM, Pellegrini VD Jr. Histopathology of the palmar beak ligament in trapeziometacarpal osteoarthritis. *J Hand Surg Am.* 1999;24(3):496–504.
- Van Heest AE, Kallemeier P. Thumb carpal metacarpal arthritis. *J Am Acad Orthop Surg.* 2008;16(3):140–151.
- Bouchlis G, Bhatia A, Asfazadourian H, Touam C, Vacher C, Oberlin C. Distal insertions of abductor pollicis longus muscle and arthritis of the first carpometacarpal joint in 104 dissections. *Ann Chir Main Memb Super.* 1997;16(4):326–338.
- Moreno R, Bhandari L. FCR interposition arthroplasty for concomitant STT and CMC arthritis. *Tech Hand Up Extrem Surg.* 2019;23(1):10–13.
- Desai MJ, Brogan DM, Richard MJ, Mithani SK, Leversedge FJ, Ruch DS. Biomechanical comparison of suture-button suspensionplasty and LRTI for basilar thumb arthritis. *Hand (N Y).* 2016;11(4):438–443.
- Friebel TR, Walbeehm ET, Kleinrensink GJ, Ray S, Zuidam JM. An anatomical study on the effectiveness of Arthrex Mini TightRope(l) ligament reconstruction in an unstable trapeziometacarpal joint. *Arch Orthop Trauma Surg.* 2018;138(7):1029–1033.
- Hooke AW, Parry JA, Kakar S. Mini Tightrope fixation versus ligament reconstruction—tendon interposition for maintenance of post-trapeziectomy space height: a biomechanical study. *J Hand Surg Am.* 2016;41(3):399–403.
- DeGeorge BR Jr, Chawla SS, Elhassan BT, Kakar S. Basilar thumb arthritis: the utility of suture-button suspensionplasty. *Hand (N Y).* 2019;14(1):66–72.
- Yao J. Suture-button suspensionplasty for the treatment of thumb carpometacarpal joint arthritis. *Hand Clin.* 2012;28(4):579–585.
- Yao J, Cheah AE. Mean 5-year follow-up for suture button suspensionplasty in the treatment of thumb carpometacarpal joint osteoarthritis. *J Hand Surg Am.* 2017;42(7):569 e561–569 e511.
- Yao J, Lashgari D. Thumb basal joint: Utilizing new technology for the treatment of a common problem. *J Hand Ther.* 2014;27(2):127–132; quiz 133.
- Weiss AC, Kamal RN, Paci GM, Weiss BA, Shah KN. Suture suspension arthroplasty for the treatment of thumb carpometacarpal arthritis. *J Hand Surg Am.* 2019;44(4):296–303.
- Roman PB, Linnell JD, Moore JB. Trapeziectomy arthroplasty with suture suspension: short- to medium-term outcomes from a single-surgeon experience. *J Hand Surg Am.* 2016;41(1):34–39.e31.
- Wolfe T, Chu JY, Woods T, Lubahn JD. A systematic review of postoperative hand therapy management of basal joint arthritis. *Clin Orthop Relat Res.* 2014;472(4):1190–1197.
- Elfar JC, Burton RL. Ligament reconstruction and tendon interposition for thumb basal arthritis. *Hand Clin.* 2013;29(1):15–25.
- Landes G, Gaspar MP, Goljan P, Jacoby SM, Bachoura A, Culp RW. Arthroscopic trapeziectomy with suture button suspensionplasty: a retrospective review of 153 cases. *Hand (N Y).* 2016;11(2):232–237.
- Wajon A, Vinycomb T, Carr E, Edmunds I, Ada L. Surgery for thumb (trapeziometacarpal joint) osteoarthritis. *Cochrane Database Syst Rev.* 2015;(2):CD004631.